

Project title:

**The detrimental effects of
long-term ketamine with alcohol
abuses in mice and its use in an
educational program**

Project reference no.: BDF100052

Name of grantee: Professor David T. YEW

Project date of implementation: 1 Nov 2010 to 31 Oct 2012 (2 Years)

Background

Ketamine, a noncompetitive antagonist at the glutamatergic N-methyl-D-aspartate (NMDA) receptor, is currently used in human and animal medicine as an injectable anesthetic. Ketamine is also a controlled substance, illegally used as a recreational drug. It is used primarily by young adults often at all night dance parties called “raves” that take place in nightclubs (Britt and Cance-Katz 2005). The Central Registry of Drug Abuse database (CRDA) showed different drug abuse trends in Hong Kong. The percentage of ketamine users has grown very fast, particularly from 1999 onwards. There were only few reported cases in 1999, but by 2002, the number of ketamine users was over a thousand and accounted for 70% of drug abusers under 21-year old (Joe Laidler 2005). For 3 consecutive years from 2007 to 2009, more than 85% of the total newly and previously reported abusers are ketamine users with numbers well over 2,000 (http://www.nd.gov.hk/en/statistics_list.htm). This increasing trend of ketamine abuse has also been reported worldwide (Lankenau et al 2007).

Ketamine was first synthesized in 1962 for use as an anesthetic in human and veterinary medicine (Sinner and Graf 2008). A smaller dose than the anesthetic dosage could produce a psychedelic experience of incredible intensity. The reason for prevalence use of ketamine is the lack of physical dependence and its short-lived effect with no obvious outcomes even in cases of overdose in short-term (Gable 2004). However, acute adverse effects of ketamine abuse include physiological (such as increase in heart rate, hypertension and nausea), psychological (such as hallucination, anxiety and dissociation), impairment of working memory, learning, and cognitive deficits (Ripley and Little 1995). The danger is ketamine users confused with such acute hallucinate and dissociative effects might not be aware of injury induced or related physical assaults in addition to weird behavior which could be fatal (Gable, 2004). More importantly, the long-term effects of ketamine are much more worrying, as we have published damages by ketamine long-term abuse to the brain, bladder and kidney (Yeung et al 2009, Yeung et al 2010, Mak et al 2010). Indeed, it has been shown that ketamine was toxic to hepatocytes at also low concentrations (Lee et al 2009). Furthermore, from a recent study in Hong Kong, ketamine abusers could have destruction of their lower urinary tract including syndrome of cystitis and contracted bladder, and secondary damage might be irreversible (Chu et al

2008). Therefore, long term ketamine treated animal models should be sought to study these multi-organ effects of ketamine.

In addition, ethanol is also a noncompetitive NMDA receptor antagonist that triggers similar dissociative and hallucinate effects as ketamine, as well as neurodegeneration and damage to liver (Ikonomidou et al 1999; Ikonomidou et al 2000). Alcohol drinking is certainly popular among club goers that might take ketamine at the same time (Gable 2004), the synergic or additive effects of simultaneous use of ketamine and alcohol would be much more severe than uses of alone ketamine or alcohol. This combined effect of ketamine and ethanol has not been studied and the results are definitely more important to those ketamine abusers than results of ketamine alone. Therefore, we aim to study the combined effect of ketamine and ethanol as well as their separated effects in mice with long-term ketamine on multiple internal organs in this present project. We will use this laboratory information in launching an educational program with scientific evidences for schools and youth centers; a convincing and strong message to the youngsters that indeed ketamine alone or in combination with alcohol abuses are damaging to their bodies from results by local research institution.

Materials and Methods

Our preliminary results

In the last 2 years, we have studied the long-term effects of ketamine on mice and monkeys with daily ketamine administration from 1 to 6 months. Our published results showed that the brain, bladder and kidney were damaged by ketamine, and ketamine was toxic to neurons in culture (Yeung et al 2009; Yeung et al 2010, Mak et al 2010). Our unpublished results further showed that permanent deficits in brain functions were caused by ketamine in mice with 6 months' ketamine treatment. The long-term ketamine abuse model using mice and monkeys was established (Yeung et al 2010).

In view of the fact that ethanol is also a noncompetitive NMDA receptor antagonist as ketamine (Ikonomidou et al 1999). In addition, alcohol drinking is popular among club goers that might take ketamine at the same time (Gable 2004), the synergic or additive effects of simultaneous use of ketamine and alcohol would be much more severe than uses of alone ketamine or alcohol. In our preliminary studies, we used mice that had been given ketamine (30 mg/kg) for 6 months for a further 2 weeks of combined ketamine and ethanol (1 g/kg) administration. Results showed that the liver, kidney, brain and bladder of these mice suffered from severe damages and degenerations. Therefore, we will examine in details of these possible damaging effects of ketamine on multiple internal

organs in the present proposed study.

First Stage: Animal experiment

Male ICR mice, 4 weeks old, bred in our University's animal facility will be used. Five experimental and one control groups of mice will be studied as shown in Table 1. Briefly, Group 1 will be for a short-term of 2 (1A) and 4 (1B) weeks of ketamine plus ethanol treatment; Group 2 will be for an initial short-term of 2 weeks ketamine only followed by a 4 weeks of ethanol only (2A) or ketamine plus ethanol (2B) treatment. Likewise for Groups 3 to 5, except that the initial term will be from 4 to long-term 24 weeks (Table 1). There will be 30 mice in each subgroup and therefore a total of 330 mice will be used for the whole project. Mice will be weighed every week to monitor the somatic effects of the treatment methods and the well being of the animals.

Ketamine will be given daily at a dose of 30 mg/kg, which is a recreational dose for mice as we have previously used (Yeung et al 2009; Gable 2004). Ethanol will be given daily at a dose of 1 g/kg, which is considered as low dose comparable to one to two glasses of red wine for an adult man (Hayase et al 1999). At the end of experiment, mice will be sacrificed by exsanguinations and tissue samples from the brains (prefrontal cortex, hippocampus, cerebellum and medulla oblongata), kidney, bladder, liver, heart and small intestine (proximal and distal parts) will be collected as we previously reported (Yeung et al 2009). These samples will be processed for section cutting at 10 µm for subsequent histological examination. Blood and if possible urine samples will also be collected for biochemistry analyses.

Table 1. Groups of mice proposed in this study.					
Group	N	Ketamine only	Alcohol only	Ketamine with Alcohol	Total period
Control	30	-	-	-	-
1A	30	-	-	2 weeks	2 weeks
1B	30	-	-	4 weeks	4 weeks
2A	30	2 weeks	4 weeks	-	6 weeks
2B	30	2 weeks	-	4 weeks	6 weeks
3A	30	4 weeks	4 weeks	-	8 weeks
3B	30	4 weeks	-	4 weeks	8 weeks
4A	30	12 weeks	4 weeks	-	16 weeks
4B	30	12 weeks	-	4 weeks	16 weeks
5A	30	24 weeks	4 weeks	-	28 weeks
5B	30	24 weeks	-	4 weeks	28 weeks

Second Stage: Histological examination

We will examine the tissue sections using hematoxylin and eosin and periodic acid-Schiff for morphology changes as we previously described (Li et al 2005; Yeung et al 2009; Yeung et al 2010). Damages and changes of different tissues will be compared between different treatment groups. We will also perform the terminal dUTP nick end labeling (TUNEL), a test for cell death, in selected tissue sections that show damages. Numbers of TUNEL positive cells will be compared between groups. In addition, we will perform liver function tests, cardiac enzymes and renal function tests with the blood samples and urine microscopy and protein test with the urine samples collected. These results will provide information about the effect of ketamine and alcohol on general health of the mice.

Third Stage: Educational program

At the end of the first year when preliminary results are available, we will arrange visits to schools or youth centers to propagate the scientific message of ketamine abuse alone (via the results of previous studies (Yeung et al 2009; Yeung et al 2010) and now when combined with alcohol drinking is damaging to many internal organs. Twelve to sixteen such visits will be arranged, i.e. once every 3 or 4 weeks over the second year. At the same time, we will write up the results for publication in scientific journals.

Project Objectives:

1. To document the detrimental effects of long-term uses of ketamine with alcohol on internal organs in young adult mice.
2. To bring this scientifically based information of detrimental effects of ketamine alone or combined with alcohol to youngsters in an educational program.

Results:

During this period with the support of BDF, seven scientific papers and one book chapter were published in international journals. The book chapter is in a book by Elsevier press. In addition Prof. D.T Yew has been asked to edit a book entitled "Ketamine-use and abuse" by the CRC press (U. S. A.) on the subject.

Part I: List of papers

- i) [Tan S](#), [Lam WP](#), [Wai MS](#), [Yu WH](#), [Yew DT](#) (2012). Chronic ketamine administration modulates midbrain dopamine system in mice. [PLoS One](#). 7(8) (E.Pub.).

- ii) [Wong YW, Lam LH, Tang HC, Liang Y, Tan S, Yew DT \(2012\)](#). Intestinal and liver changes after chronic ketamine and ketamine alcohol treatment. [Microscopy Research and Technique](#).75(9):1170-5.
- iii) [Wai MS, Luan P, Jiang Y, Chan WM, Therese YM, Tsui TY, Tang HC, Lam WP, Fan M, Yew DT \(2012\)](#). Long Term Ketamine and Ketamine Plus Alcohol Toxicity - What Can We Learn From Animal Models? [Mini Rev Med Chem](#). (E.Pub.).
- iv) [Wai M, Chan W, Zhang A, Wu Y, Yew D \(2012\)](#). Long-term ketamine and ketamine plus alcohol treatments produced damages in liver and kidney. [Hum Exp Toxicol](#). 31(9):877-86.
- v) [Yu H, Li Q, Wang D, Shi L, Lu G, Sun L, Wang L, Zhu W, Mak YT, Wong N, Wang Y, Pan F, Yew DT \(2012\)](#).^a Mapping the central effects of chronic ketamine administration in an adolescent primate model by functional magnetic resonance imaging (fMRI).[Neurotoxicology](#). 33(1):70-7.
- vi) [Chan WM, Liang Y, Wai MS, Hung AS, Yew DT \(2011\)](#). Cardiotoxicity induced in mice by long term ketamine and ketamine plus alcohol treatment. [Toxicol Lett](#). 207(2):191-6.
- vii) [Chan WM, Xu J, Fan M, Jiang Y, Tsui TY, Wai MS, Lam WP, Yew DT \(2012\)](#).
^b Downregulation in the human and mice cerebella after ketamine versus ketamine plus ethanol treatment. [Microsc Res Tech](#). 75(3):258-64.

- a- remain publication of last ketamine project
- b- published in between present and last project

Results- abstracts of papers

- i) Chronic ketamine administration modulates midbrain dopamine system in mice

Abstract

Ketamine is an anesthetic and a popular abusive drug. As an anesthetic, effects of ketamine on glutamate and GABA transmission have been well documented but little is known about its long-term effects on the dopamine system. In the present study, the effects of ketamine on dopamine were studied *in vitro* and *in vivo*. In pheochromocytoma (PC 12) cells and NGF differentiated-PC 12 cells, ketamine decreased the cell viability while increasing dopamine (DA) concentrations in a dose-related manner. However, ketamine did not affect the expression of genes involved in DA synthesis. In the long-term (3 months) ketamine treated mice, significant increases of DA contents were found in the midbrain. Increased DA concentrations were further supported by up-regulation of tyrosine hydroxylase (TH), the rate limiting enzyme in catecholamine synthesis. Activation of midbrain dopaminergic neurons could be related to ketamine modulated cortical-subcortical glutamate connections. Using western blotting, significant increases in BDNF protein levels were found in the midbrain, suggesting that perhaps BDNF pathways in the cortical-subcortical connections might contribute to the long-term ketamine induced TH upregulation. These data suggest that long-term ketamine abuse caused a delayed and persistent upregulation of subcortical DA systems, which may contribute to the altered mental status in ketamine abusers

ii) Intestinal and liver changes after chronic ketamine and ketamine alcohol treatment.

Abstract

The effects of long-term chronic ketamine treatment on the intestine and the liver were studied in the ICR mice which had daily intraperitoneal injection of ketamine at 30 mg/kg per day for 7 months. The intestine showed no significant pathology after treatment but had a decrease of the positive sites of proliferative cell nuclear antigen in the mucosae of the intestines after ketamine and ketamine plus alcohol (added in the last month) treatment. No significant apoptosis (via TUNEL) nor necrosis (via lactic acid dehydrogenase) was detected in the intestines of all control and ketamine-treated groups, with the exception of an increase of lactic acid dehydrogenase in the mucosae of the intestines of the ketamine plus alcohol group. In the liver, loss of glycogen was observed in animals after ketamine and ketamine plus alcohol treatment, in addition to the pathology reported in a previous work. The decrease in quantity of glycogen in the liver reflected either a failure of glycogen synthesis from glucose or an increase of glycogenolysis in the liver.

iii) Long Term Ketamine and Ketamine Plus Alcohol Toxicity - What Can We Learn From Animal Models?

Abstract

This review addressed the adverse effects of the frequently-used recreational drug, ketamine through using mice and monkey models. Our laboratory has documented initially that ketamine can induce the formation of hyperphosphorylated tau (hypertau), which is a hallmark of Alzheimer's disease (AD), in the cerebral cortex of both mice and monkeys as well as apoptosis in neurons in these species. Besides the cerebral cortex, other centers in the central nervous system (CNS) and peripheral nervous system (PNS) are also influenced by ketamine. Cerebellum was found to be down-regulated in both mice and humans after long-term of ketamine administration and it was caused by the apoptosis of Purkinje cells. Deleterious effects in other organs reported in long-term ketamine users include of kidney dysfunction leading to proteinuria, fibrosis of the urinary bladder and reduction in size of the urinary bladder leading to frequent urination, increase of liver fibrosis and cardiac problems such as premature ventricular beats. Moreover, ketamine is usually co-administrated with other chemicals such as caffeine or alcohol. It has been reported increased harmful effects when ketamine was used in combination with the above substances. Mechanisms of damages of ketamine might be due to 1) up-regulation of NMDA receptors leading to overestimation of glutamatergic system or 2) the metabolite of ketamine which was a hydroquinone exerted toxicity.

iv) Long-term ketamine and ketamine plus alcohol treatments produced damages in liver and kidney.

Abstract

Ketamine is one of the common recreational drugs used in rave parties and it is frequently taken with alcohol. In spite of this, the potential toxicity of ketamine in liver and kidney has not been fully documented. In this study, ICR mice were treated for periods of 6, 16 and 28 weeks with 30 mg/kg ketamine injected daily intraperitoneally, and together with alcohol (0.5 ml of 10% alcohol for each mouse) during the last 4 weeks of the treatment periods. Our experimental results showed significant damage in liver, including fatty degeneration of liver cells, fibrosis and increase in liver glutamic oxaloacetic transaminase, proliferative cell nuclear antigen and lactate dehydrogenase after 16 weeks of treatment with ketamine. Hydropic degenerations of the kidney

tubules were observed as early as 6 weeks of treatment. Long-term ketamine administration (28 weeks) led to atresia of glomeruli in the kidney. Proteinuria was confirmed in the 67% of the ketamine-treated animals after 28 weeks of treatment. It was apparent that ketamine when taken chronically (16 weeks of treatment and thereafter) affected both liver and kidney definitively. The damages in both liver and kidney of these mice were more severe when the animals were treated with both ketamine and alcohol.

v) Mapping the central effects of chronic ketamine administration in an adolescent primate model by functional magnetic resonance imaging (fMRI).

Abstract

Ketamine, a noncompetitive N-methyl-D-aspartic acid (NMDA) receptor antagonist, is capable of triggering excessive glutamate release and subsequent cortical excitation which may induce psychosis-like behavior and cognitive anomalies. Growing evidence suggests that acute ketamine administration can provoke dose-dependent positive and negative schizophrenia-like symptoms. While the acute effects of ketamine are primarily linked to aberrant activation of the prefrontal cortex and limbic structures with elevated glutamate and dopamine levels, the long-term effects of ketamine on brain functions and neurochemical homeostasis remain incompletely understood. In recent years, reports of ketamine abuse, especially among young individuals, have surged rapidly, with profound socioeconomic and health impacts. We herein investigated the chronic effects of ketamine on brain function integrity in an animal model of adolescent cynomolgus monkeys (*Macaca fascicularis*) by functional magnetic resonance imaging (fMRI). Immunohistochemical study was also conducted to examine neurochemical changes in the dopaminergic and cholinergic systems in the prefrontal cortex following chronic ketamine administration. Our results suggest that repeated exposure to ketamine markedly reduced neural activities in the ventral tegmental area, substantia nigra in midbrain, posterior cingulate cortex, and visual cortex in ketamine-challenged monkeys. In contrast, hyperfunction was observed in the striatum and entorhinal cortex. In terms of neurochemical and locomotive changes, chronically ketamine-challenged animals were found to have reduced tyrosine hydroxylase (TH) but not choline acetyltransferase (ChAT) levels in the prefrontal cortex, which was accompanied by diminished total movement compared with the controls. Importantly, the mesolimbic, mesocortical and entorhinal-striatal systems were found to be functionally vulnerable to ketamine's chronic effects. Dysfunctions of these neural circuits have been implicated in several neuropsychiatric disorders

including depression, schizophrenia and attention deficit disorder (ADD). Collectively, our results support the proposition that repeated ketamine exposure can be exploited as a pharmacological paradigm for studying the central effects of ketamine relevant to neuropsychiatric disorders.

vi) Cardiotoxicity induced in mice by long term ketamine and ketamine plus alcohol treatment.

Abstract

Increased use of ketamine as a recreational drug in rave party has raised lots of social concerns. Although its toxicity on the central nervous system (CNS) and urinary system had been reported, its potential adverse effects on the heart is still not addressed. Using our long term ketamine addiction model in which, 1-month-old ICR mice were given ketamine intraperitoneally (i.p. 30 mg/kg) for different study periods (6 weeks, 16 weeks and 28 weeks). The electrocardiogram (ECG) and the level of troponin as well as the presence of lactate dehydrogenase were used together to determine the cardiac function of mice. ST elevations were observed in 30% of mice from 6 weeks onwards. Concomitant increase in troponin in serum and presence of lactate dehydrogenase positive cardiac cells were taken together to indicate cardiac damages. The potential interactive effects of alcohol (ethanol) and ketamine were also addressed and 0.5 ml of 10% ethanol was administrated additionally to the mice daily and orally for the last 4 weeks in the 28-week long-term ketamine treated animals. The cardiac functions of these mice deteriorated more severely as indicated by further rise in troponin levels. In addition, high number of lactate dehydrogenase positive cardiac cells and abnormal ECGs in both ketamine and ketamine plus alcohol treated models also gave coherent conclusions.

vii) Downregulation in the human and mice cerebella after ketamine versus ketamine plus ethanol treatment.

Abstract

To study the deleterious effects of ketamine and the potential interaction effects between ethanol and ketamine on the cerebellum, functional magnetic resonance imaging (fMRI) tests were performed on the habitual ketamine users (n = 3) when they flexed and extended their upper limbs. Another fMRI test was performed on the same participants in which they consumed alcohol (12%, 200 mL) 1 h before the test.

Downregulation on the activity of cerebellum was observed and the level of activation in the cerebellum decreased dramatically in habitual ketamine users with alcohol consumption before the test. Further studies were performed by using male ICR mice receiving treatment of ketamine only [30 mg kg(-1) intraperitoneally (i.p.)] or ethanol only everyday (0.5 mL 12% orally) and those with coadministration of the above dosages of ketamine and ethanol for 3 months. Fewer Purkinje cells were observed in the cerebellar sections of ketamine treated mice under silver staining. For TUNEL test, a significant increase in the apoptotic cells were observed in the cerebella of the ketamine treated mice ($P = 0.016$) and of those with co-administration of ketamine and ethanol ($P < 0.001$), when compared with the control. A statistical significance ($P < 0.001$) in two-way ANOVA test indicated that there might be an interactive mechanism between ethanol and ketamine acting on the cerebellum.

Book and book chapters

- 1) Prof D. T. Yew has been asked to edit a book for the CRC press USA, entitled “Ketamine: Use an Abuse”. The book contains 15 chapters and will come out in print by 2014. Contributors include authors from USA, UK, Canada, Italy, China and locally.
 - 2) Prof D.T. Yew wrote a chapter for the book “Novel Psychoactive Substances: Classification, Pharmacology and Toxicology, “edited by Paul Dargan and David Wood, National Health Service and Guys’ hospital, UK and Published by Elsevier. The chapter’s title is “Ketamine”.
- a) Highlight of results
- 1) Nervous system- chronic ketamine (3 months) produced downregulation of the cerebellum, prefrontal cortex but upregulated the midbrain dopamine. This latter is important as the midbrain irregularities can lead to schizophrenia. Prolonged use of ketamine led to neuronal degeneration aggravated with the combined use of alcohol.
 - 2) Heart- ketamine chronic usage (3 months) led to increase of blood troponin (indicating cardiac damage) and upregulated cellular lactate dehydrogenase. Premature ventricular beats were features which deteriorated with combination of alcohol, highlighted by ST wave inversion (ischemic heart) in experimental subjects.
 - 3) Liver-increase of transaminase, lactate dehydrogenase, proliferative cell nuclear antigen all indicated cellular damage and could be seen 3-4 months after ketamine treatment. Longer ketamine led to fibrosis of liver. Combination of alcohol increases the toxic response by 20% to 30% in

elevation of enzymes and increased intensity of fibrosis, with severe loss of glycogen in the liver.

- 4) Kidney showed atresia of some glomeruli after 28 weeks of ketamine with evident proteinuria. There were at least 10% more affected glomeruli after combined alcohol use for 4 weeks.
- 5) Urinary bladders subjected to ketamine revealed inflammation and fibrosis. Both increased upon usage of alcohol.
- 6) In the intestine, there was a mild increase of lactate dehydrogenase in the mucosa, with large lymphoid nodules after combined alcohol/ ketamine. In the stomach, there was an increase of parietal cells versus mucous cells, also aggravated by addition of alcohol.
- 7) Nasal intake of ketamine led to fibrosis of lung, intensified by combined alcohol. Lung fibrosis in the long term, although not painful like the bladder, had grave consequence and was not reversible. More research should be aim at this domain.
- 8) Comparison of cell death in different organs were studied by TUNEL method and representative results were demonstrated in the following figures (unpublished).

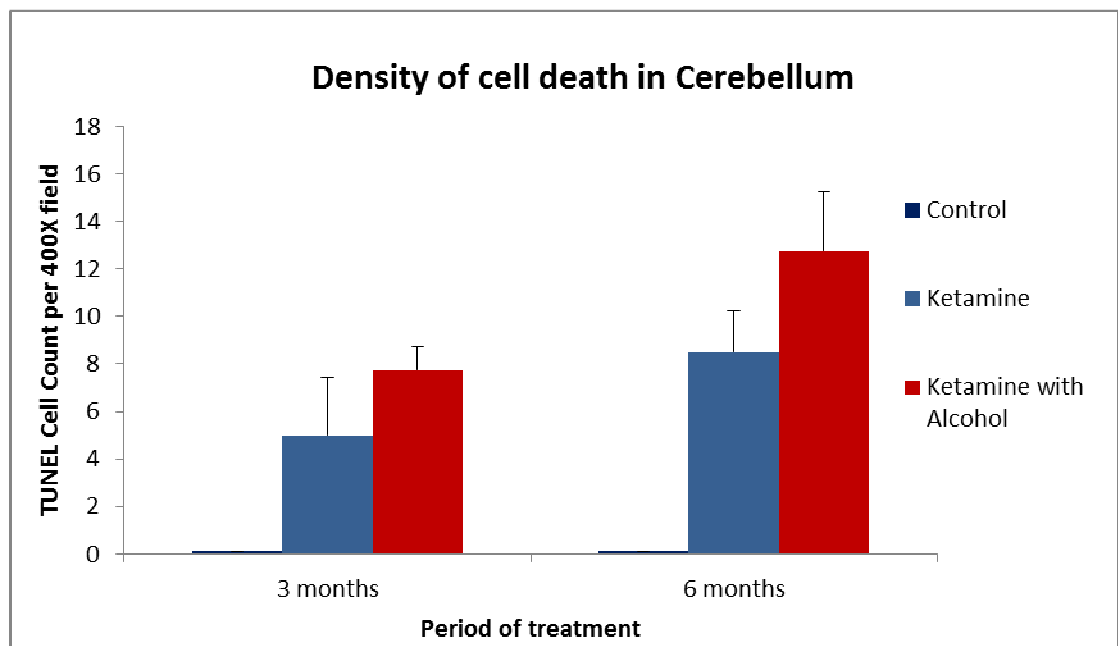


Fig 1.

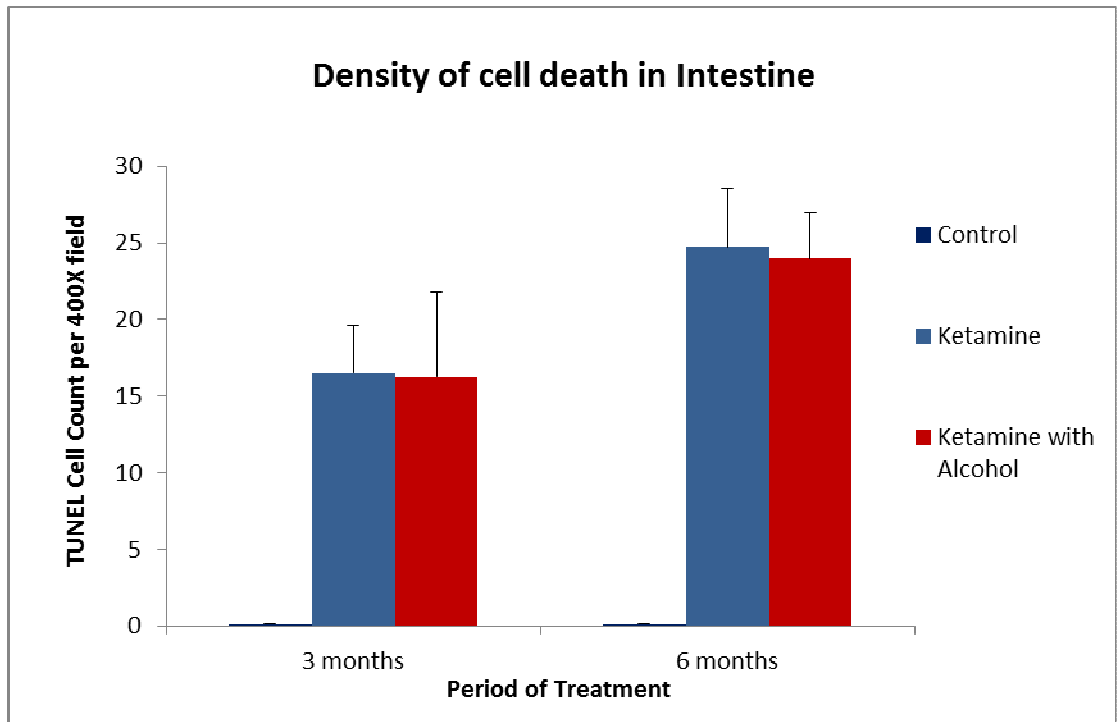


Fig 2.

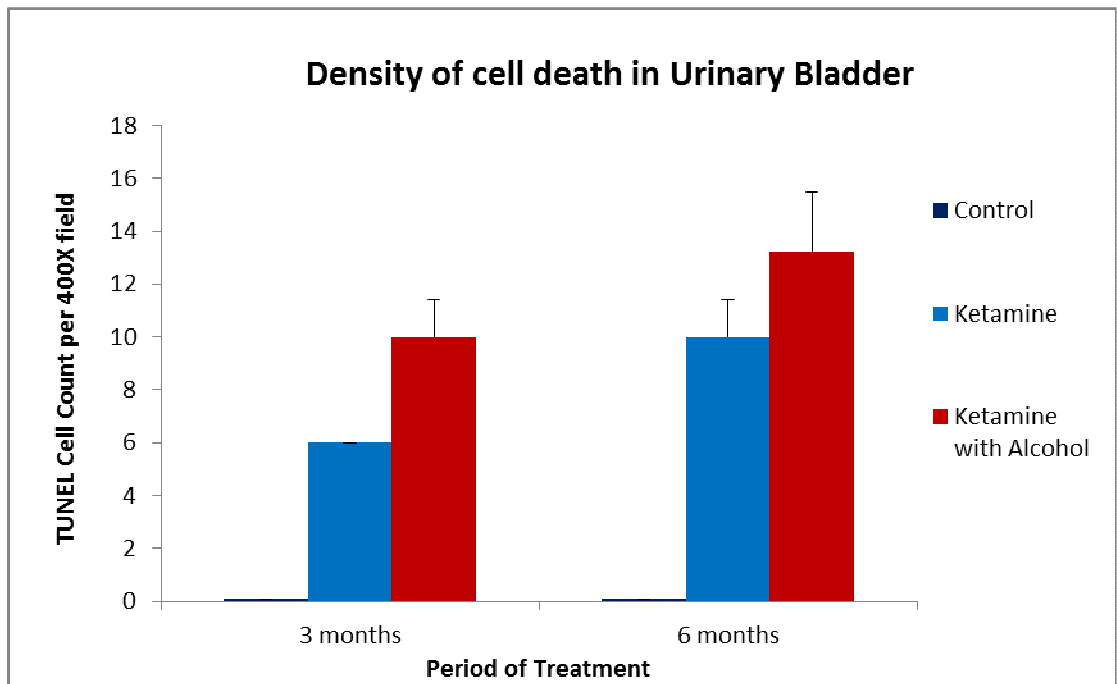


Fig 3.

In the central nervous system shown here as in the cerebellum, both ketamine and ketamine plus alcohol increased apoptotic cell death, with ketamine plus alcohol being most severe. The increase was prominent after 3-6 month of ketamine treatment.

In the intestine, on the other hand, treatment with ketamine and ketamine plus alcohol both increased apoptotic cell death, but there was no significant difference between the two.

In the urinary system, using the urinary bladder as example, like other organs, ketamine alone and ketamine plus alcohol both increased apoptotic cell death, again with ketamine plus alcohol being most severe. The trend was evident after 3 months of ketamine treatment.

Part II School Talks

- a) List of school lectures and number of participants for each

Title of school lecture:

The Detrimental Effects of Long-term Ketamine with Alcohol Abuses in Mice and its Use in an Educational Program 氯胺酮及酒精對小鼠的影響 (研究與教育)

<u>Name of School</u>	<u>No. of Student</u>
1. HKU SPACE (Admiralty)	23
2. HKU SPACE (Kowloon Bay)	48
3. Hong Kong Baptist University Affiliated School Wong Kam Fai Secondary School	118
4. Tack Ching Girls Middle School	202
5. Chong Gene Hang College	322
6. Po Leung Kuk Centenary Li Shiu Chung Memorial College	200
7. Ko Lui Secondary School	246
8. Tin Ka Ping Secondary School	181
9. Sha Tin Methodist college	177
10. United Christian College	56
11. The Mission Covenant Church Holm Glad College	341
12. <u>Tsung Tsin Christian Academy</u>	<u>156</u>
Total	2,070

b) Statistics for questionnaires

i) Questionnaire

ii) Statistics

Overall statistics

氨胺酮及酒精對小鼠的影響(研究與教育)

講座後評估問卷(結果分析)

1)對這次講座的感覺如何? 不好(4.9%) 適合(49.2%) 很好(45.9%)

2)這次講座的時間長短 較短(6.6%) 適合(79.2%) 較長(14.2%)

3)這次講座有否令你更了解 K 仔的害處? 有(94.9%) 無(5.1%)

4)你是否希望日後有多些此類講座? 不希望(9.3%) 無意見(50.0%) 希望(40.7%)

5)講座後的問答時段是否有幫助? 是(45.8%) 無意見(48.3%) 否(5.9%)

8)你同學中有否用 K 仔? 無(93.3%) 有幾個(3.8%) 很多(2.9%)

9)他們有否參與這次講座? 有(41.4%) 無(58.6%)

10)講座後的問答時段是否需要延長? 是(14.7%) 否(85.3%)

	非常不同意	不同意	很難說	同意	非常同意
11)吸食 K 仔令人不能控制自己的行爲	2.5 %	0.7 %	9.0 %	42.4 %	45.5 %
12)吸食 K 仔會損害判斷能力與思考	2.3 %	0.7 %	6.1 %	35.5 %	55.4 %
13)吸食 K 仔會導致記憶衰退	2.3 %	0.4 %	6.7 %	36.9 %	53.8 %
14)吸食 K 仔會產生幻覺	2.2 %	1.1 %	7.9 %	37.4 %	51.4 %
15)吸食 K 仔會傷害腎臟及膀胱	2.1 %	0.5 %	5.5 %	33.3 %	58.6 %
16)吸食 K 仔亦可傷害心臟及肝臟	1.9 %	0.6 %	6.1 %	34.5 %	56.9 %
17)用 K 仔最後會引致精神失常	2.2 %	0.8 %	10.6 %	36.3 %	50.2 %
18)K 仔加上其他有害物可引致更嚴重的傷害	2.2 %	0.7 %	7.1 %	29.7 %	60.4 %

Conclusive remark on school lectures:

On the whole, the lectures and interactions in all the twelve institutions (10 high school and two community colleges) were quite successful. The number of students exceeded the target. The majorities of students found the contents interesting and in a few schools, the interaction (Q & A) after the meeting was both educational for this speaker and the students. The statistics enclosed show a definitive positive trend and over 90% of the students present concluded that they had a clearer image of the toxic effects of ketamine (see attached summary of statistics). The schools were selected on the base that they were not on the top of academic achievements of high schools and they were usually in areas where ketamine addiction was a problem. As the speaker, I found this exercise rewarding and would suggest the Beat Drug Fund to stage more of these lectures to schools. On the other hand, it is important to have the right speakers who knows the detailed effects of particular drugs. An occasional visit by a health nurse or a police office may not have the equivalent impact.

Conclusion**Final Conclusion:**

In conclusion, the project has been reasonably successful. We have achieved the two aims listed in the application. In the first aim, scientific evidences from this group have documented the effects of ketamine on various organs and the additional damages with alcohol. These results were published in international scientific journals and an invited chapter. We have now received requests to collaborate, in fact already had collaborated with institutions in Europe and America, notably the Toxicology Institute of the National Health Service of UK. We have also established links with major forensic institutes in China. With these tiny contributions, we have at least put the name of Hong Kong on the world Map of Drug Abuse Research. I hope this trend can flourish into the future.

For the second aim (school visits), I had to must say it was a lot of joy to interact with these students. They were inquisitive, willing to learn and interact and I had encountered no defensive behaviors. In reality, we have now had requests from students of many schools to visit own laboratory and see how the research is conducted. This may be another angle that the Beat Drug Fund can think about, supporting students in this sort of laboratory activities so that they have a first hand knowledge of damages and suffering after abusive drug intoxication.

The project was quite smooth and we have had no major setbacks. Ketamine studies are, however, never exhaustive. There are many items down the road that need to be

addressed. For example, if ketamine sniffing via the nose can damage the lung, how can this be effectively controlled and treated. How does ketamine affect the pregnant mother and the fetus? Many more of these questions can be asked. It is for the management of the BDF to balance the funding of frontline workers, clinical and basic researches, bearing in mind that basic research on animals is nonetheless a first step of “possible” extrapolation onto human. A healthy and forward going Funding Agency (e.g. National Institutes of Health in USA has an Institute of Drug Abuse) must support front line work as well as research. For us, we thank the BDF for supporting us in two proposals (the past and this one).

Reference

- Britt GC, Cance-Katz EF (2005). A brief overview of the clinical pharmacology of "club drugs". *Subst Use Misuse*. 40:1189-1201.
- Chu PS, Ma WK, Wong SC, Chu RW, Cheng CH, Wong S, Tse JM, Lau FL, Yiu MK, Man CW (2008). The destruction of the lower urinary tract by ketamine abuse: a new syndrome? *BJU Int*. 102:1616-1622.
- Gable RS (2004). Acute toxic effects of club drugs. *J Psychoactive Drugs*. 36:303-313.
- Hayase T, Yamamoto Y, Yamamoto K (1999). Role of cocaethylene in toxic symptoms due to repeated subcutaneous cocaine administration modified by oral doses of ethanol. *J Toxicol Sci*. 24: 227-235.
- Ikonomidou C, Bittigau P, Ishimaru MJ, Wozniak DF, Koch C, Genz K, Price MT, Stefovská V, Hörster F, Tenkova T, Dikranian K, Olney JW (2000). Ethanol induced apoptotic neurodegeneration and fetal alcohol syndrome. *Science*. 287: 1056–1060.
- Ikonomidou C, Bosch F, Miksa M, Bittigau P, Vockler J, Dikranian K, Tenkova TI, Stefovská V, Turski L, Olney JW (1999). Blockade of NMDA receptors and apoptotic neurodegeneration in the developing brain. *Science*. 283: 70-74.
- Joe Laidler KA (2005). The rise of club drugs in a heroin society: the case of Hong Kong. *Subst Use Misuse*. 40: 1257-1278.
- Lankenau SE, Sanders B, Bloom JJ, Hathazi D, Alarcon E, Tortu S, Clatts MC (2007). First injection of ketamine among young injection drug users (IDUs) in three U.S. cities. *Drug Alcohol Depend*. 87: 183-193.
- Lee ST, Wu TT, Yu PY, Chen RM (2009). Apoptotic insults to human HepG2 cells induced by S-(+)-ketamine occurs through activation of a Bax-mitochondria-caspase
- Li L, Lu G, Yao H, Zhao Y, Feng Z, Yew DT (2005). Postmortem changes in the central nervous system and adrenal medulla of the heroin addicts. *Int J Neurosci*. 115: 1443-1449.
- Mak YT, Lam WP, Lü L, Wong YW, Yew DT (2010). The toxic effect of ketamine on

- SH-SY5Y neuroblastoma cell line and human neuron. *Microsc Res Tech.* 73: 195-201.
- Ripley TL, Little HJ (1995). Effects on ethanol withdrawal hyper-excitability of chronic treatment with a competitive N-methyl-D-aspartate receptor antagonist. *J Pharmacol Exp Ther.* 272: 112-118.
- Sinner B, Graf BM (2008). Ketamine. *Handb Exp Pharmacol.* 182: 313-333.
- Yeung LY, Rudd JA, Lam WP, Mak YT, Yew DT (2009). Mice are prone to kidney pathology after prolonged ketamine addiction. *Toxicol Lett.* 191: 275-278.
- Yeung LY, Wai MS, Fan M, Mak YT, Lam WP, Li Z, Lu G, Yew DT (2010). Hyperphosphorylated tau in the brains of mice and monkeys with long-term administration of ketamine. *Toxicol Lett.* 193: 189-193.